

Ablative Skin Resurfacing With a Novel Microablative CO₂ Laser

Robert H. Gotkin MD,^a Deborah S. Sarnoff MD,^b Giovanni Cannarozzo MD,^c Neil S. Sadick MD,^d Macrene Alexiades-Armenakas MD PhD^e

a. Private practice, New York, NY

b. Clinical Professor, Department of Dermatology, New York University School of Medicine, New York, NY

c. Dermatologic Clinic, University of Florence, Florence, Italy

d. Clinical Professor of Dermatology, Weill Medical College of Cornell University, New York, NY

e. Assistant Clinical Professor, Yale University School of Medicine, Boston, MA

ABSTRACT

Carbon dioxide (CO₂) laser skin resurfacing has been a mainstay of facial rejuvenation since its introduction in the mid 1990s. Recently, a new generation of fractional or microablative CO₂ lasers has been introduced to the marketplace. According to the concept of fractional photothermolysis, these lasers ablate only a fraction of the epidermal and dermal architecture in the treatment area. An array of microscopic thermal wounds is created that ablates the epidermis and dermis within very tiny zones; adjacent to these areas, the epidermis and dermis are spared. This microablative process of laser skin resurfacing has proven safe and effective not only for facial rejuvenation, but elsewhere on the body as well. It is capable of improving wrinkles, acne scars, and other types of atrophic scars and benign pigmented lesions associated with elastotic, sun-damaged skin. Because of the areas of spared epidermis and dermis inherent in a procedure that employs fractional photothermolysis, healing is more rapid compared to fully ablative CO₂ laser skin resurfacing and downtime is proportionately reduced.

A series of 32 consecutive patients underwent a single laser resurfacing procedure with the a new microablative CO₂ laser. All patients were followed for a minimum of 6 months and were asked to complete patient satisfaction questionnaires; a 6 month post-operative photographic evaluation by an independent physician, not involved in the treatment, was also performed. Both sets of data were graded and reported on a quartile scale. Results demonstrated greater than 50% improvement in almost all patients with those undergoing treatment for wrinkles, epidermal pigment or solar elastosis deriving the greatest change for the better (>75%).

INTRODUCTION

Carbon dioxide (CO₂) laser skin resurfacing has been the gold standard for cutaneous facial resurfacing of photo-damaged skin since its emergence in the marketplace in the mid 1990s.¹⁻⁴ There were many high energy, pulsed, and continuous wave scanned CO₂ lasers ($\lambda = 10\ 600\ \text{nm}$) used at that time—all of which adhered to the principles of selective photothermolysis, but with differences in the exact characteristics of the energy being emitted. Although this technology was excellent for the treatment of facial wrinkles,¹⁻³ acne scars,⁵⁻⁶ and sun damage and solar elastosis, it fell into some disfavor due to its inability to be used off the face; its requirement for effective anesthesia; the nature of, and downtime associated with, the recovery following treatment; and the significant risk of dyschromia and scarring. Prolonged postoperative erythema and transient hyperpigmentation were common findings; late (greater than 1 year postoperatively) hypopigmentation was also not uncommon. These side effects and complications plagued even the most cautious practitioners and well-chosen patients.⁷⁻¹⁴

Nonablative laser resurfacing and intense pulsed light systems were introduced in an attempt to replace fully ablative CO₂ and

erbium:YAG laser resurfacing; the promise was the stimulation of dermal collagen remodeling and neocollagenesis with no epidermal injury and virtually no healing or downtime.¹⁵ Wavelengths used were both in the visible and near infrared range. Pulsed dye lasers (585 nm and 595 nm), the 532-nm potassium titanyl phosphate (KTP) laser, and intense pulsed light (IPL; 550-1200 nm) systems were devices in the visible range of wavelengths. Near infrared wavelength systems were the 1064-nm Nd:YAG, 1320-nm Nd:YAG, 1450-nm diode laser, and 1540-nm erbium-doped phosphate glass laser. All of these systems showed microscopic changes in dermal collagen. Some systems even demonstrated histologic evidence of neocollagenesis, but all fell short of anything more than very mild clinical improvement in the appearance of photodamaged skin. Often, there was no visible clinical improvement noted. Since there was no epidermal injury, there was no significant tightening of wrinkled, lax, solar elastotic skin.¹⁶

The concept of fractional photothermolysis (FP) was described by Manstein et al in 2004.¹⁷ Fractional photothermolysis thermally alters only a fraction of the epidermal and/or dermal architecture leaving intervening areas unchanged. These intact

bridges of unaltered skin between the microscopic treatment zones (MTZs) result in rapid healing because the healing occurs not only from the adnexa, but also from the adjacent intact skin bridges (Figure 1).

The first lasers to employ the concept of FP were in the near to mid infrared wavelength range; all are considered nonablative fractional in nature. Wavelengths utilized are the 1550nm erbium-doped fiber laser, the 1540 nm erbium glass laser, 1320 nm Nd:YAG and 1440 nm Nd:YAG lasers.¹⁶ These laser systems penetrate into the dermis, with little to no ablative effect on the epidermis, and cause tiny cores of microscopic thermal coagulation within the dermis. These cores of coagulation necrosis within the dermis slough over a few days and neocollagenesis and collagen remodeling occur. With the absence of any significant epidermal disruption, the term, nonablative fractional resurfacing has been employed. The advantages of nonablative fractional resurfacing compared to standard CO₂ ablative resurfacing, are faster healing, minimal downtime, and fewer side effects. Although these are patient-friendly advantages, the results of most nonablative fractional treatments still leave much to be desired in the treatment of rhytides, scars, and photodamaged, solar elastotic skin.¹⁸

The pendulum has swung gradually back towards ablative resurfacing because physicians and patients want more dramatic clinical results. The combination of fractional photothermolysis and CO₂ lasers gave rise to the fractional or microablative CO₂ laser technology used today.¹⁹ Ablative fractional skin resurfacing with a CO₂ laser ablates portions of both the epidermis and the dermis.²⁰⁻²¹ It successfully treats wrinkles, acne scars and other types of scars, striae, benign pigmented lesions such as lentigines, solar elastoses, and other features of aged or photodamaged skin.²²⁻²⁴ Due to the features of FP, it can be used off the face and elsewhere on the body; such areas as the neck, chest, and upper and lower extremities can be treated safely with ablative fractional resurfacing.

In addition to being able to be used off the face, this fractionally ablative technology also can reduce healing and downtime as well as the potential for the side effects and complications associated with traditional, fully ablative CO₂ laser skin resurfacing. While the ablative quality of the treatment delivers excellent results in wrinkled, photodamaged, solar elastotic, or scarred skin, the fractional quality of the treatment reduces intraoperative discomfort, postoperative pain, and healing time and allows for treatment to be performed both off the face and elsewhere on the body.

METHODS

A microablative CO₂ laser system (SmartXide DOT™; DEKA, Calenzano, Italy), consisting of a 30 W CO₂ laser and a DOT scanning handpiece, was evaluated for the treatment of wrinkles,

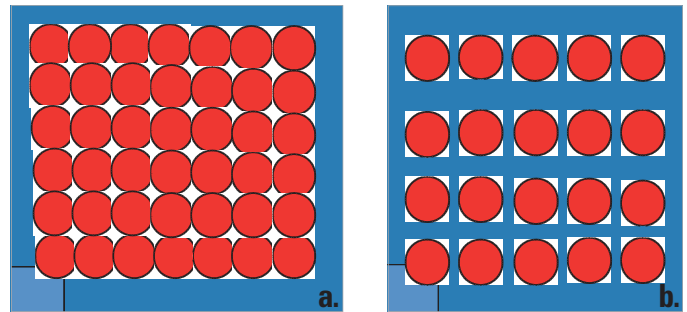


FIGURE 1. a) Red areas are the zones of ablation in fully ablative standard resurfacing; b) Red areas are the microscopic treatment zones (MTZs) of fractional photothermolysis (FP) and the blue areas are the bridges of intact, unaltered skin.

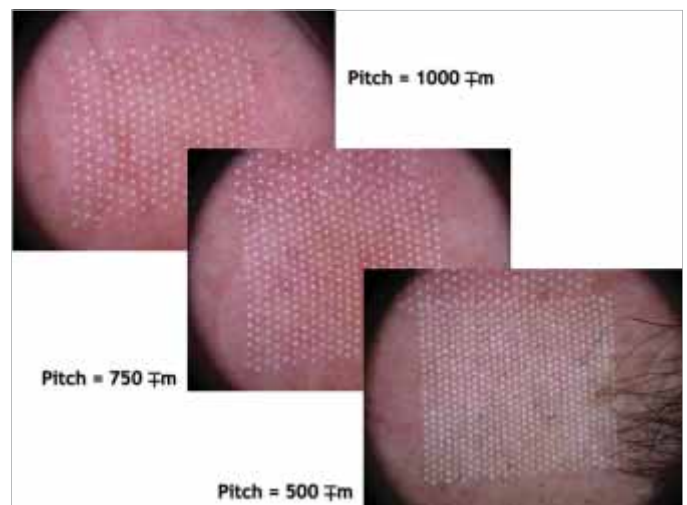


FIGURE 2. Variations in DOT pitch – the spacing between the DOTs, or microscopic treatment zones – one of the variables that confer versatility in treatment with the microablative CO₂ laser system.

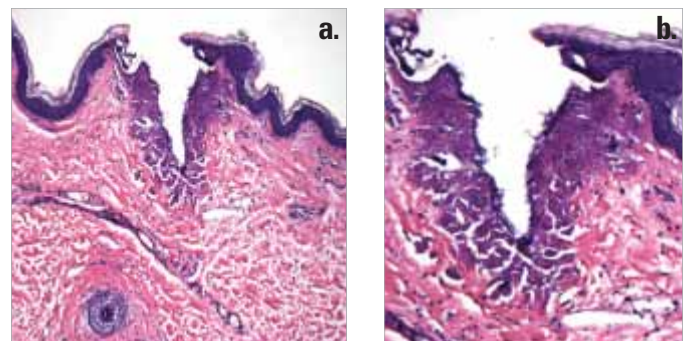


FIGURE 3. Histologic pulse profile of the microablative CO₂ laser at a) low power: pyramidal shape of the zone of ablation and the wide area of surrounding residual thermal damage; and b) high power: significant basophilic zone of residual thermal damage surrounding the zone of ablation (hematoxylin and eosin stain; magnification X40 and X100, respectively).

acne scars, striae, actinic bronzing, and discrete pigmented lesions associated with solar elastotic, sun-damaged skin (eg, lentigines). The software in the laser allows the scanner to deliver multiple tiny cores of ablative thermal damage to the epidermis and dermis. The wide range of choices in the parameters of the laser and scanning software—wattage, pulse duration and DOT pitch or the spacing between each microscopic area of thermal damage—makes this laser extraordinarily versatile. The maximum spot size on the surface of the skin is 350 microns (μm) and the maximum power is 30 W. The pulse duration varies between 200 and 2000 microseconds (μsec); the DOT pitch or spacing – the distance between the DOTs – varies between 200 and 2000 μm (Figure 2). Other user variables include the “stacking” of pulses and the number of passes over a given treatment area. The level of dermal penetration varies according to the thickness of the skin and the treatment parameters chosen and ranges from superficial to deep dermal. Depending upon the nature of the problem being treated, the microablative CO₂ laser can be used in a variety of different ways. In addition to micro-ablative resurfacing, the laser also can be used as a continuous wave, scanned, fully ablative CO₂ laser and, with a change of hand pieces, the scanner can be removed and cutting or sculpting hand pieces can be used. The latter are particularly useful in the treatment of atrophic acne scars.

A series of 32 consecutive patients, ages 33 to 76, seven men and 25 women, with Fitzpatrick skin types 1 to 3 were treated over a 3-month period from January 2008 to April, 2008. Areas treated included the face, neck, trunk and extremities. In facial resurfacing, no spot treatments were performed. If the entire face was not treated, entire cosmetic units were treated. Spot treatments were only used for benign pigment off the face, striae and scars. Exclusion criteria included any history of immunoincompetence or active systemic disease that might interfere with wound healing; any active local or systemic infection; a history of keloid formation, connective tissue disorders, or oral retinoids during the 12 months prior to treatment; a history of topical steroids or topical retinoids during the 3 months prior to treatment; any other laser or cosmetic treatment to the area being treated during the 6 months prior to treatment. Other exclusion criteria were pregnancy and/or lactation, a history of allergy to any medications necessary for treatment, unrealistic expectations or body dysmorphic disorder. Although Fitzpatrick skin types 4 to 6 were not included in this study, it is possible to treat such patients with strict management of the postoperative course and the patients’ understanding that postinflammatory hyperpigmentation will occur.

A single laser resurfacing treatment was performed. Preoperative photographs were taken immediately prior to treatment and postoperative photographs were taken at 1 week, 2 weeks and 4 weeks, 3 months, and 6 months following treatment. Some patients had punch biopsies taken from the postauricular areas to demonstrate the histologic sequence of healing. Anesthesia

varied from topical anesthetics and forced cold air to intravenous sedation and general anesthesia depending upon patient preference and other procedures being simultaneously performed. If topical anesthetic creams were used, they were completely removed prior to treatment and the skin was thoroughly degreased and dried to remove any moisture that could interfere with the ability of the laser to reach the desired target. If the eyelids or periorbital areas were being treated, stainless steel corneal shields were employed; topical tetracaine drops and appropriate lubrication on the inner, concave surface of the corneal shields was also employed.

Depending upon the severity of the problems being addressed by microablative CO₂ laser resurfacing (DOT Therapy™), a single or multiple passes – with or without stacking of pulses – was employed. Pulse energies ranged from 10 mJ to 60 mJ per pulse and DOT spacing ranged from 200 microns to 800 microns. Most patients (28 out of 32 [88%]) were treated with topical anesthetics and forced cold air; the topical anesthetic was thoroughly removed and the skin degreased with acetone prior to commencing laser treatment. Four patients were treated under intravenous sedation or general anesthesia either at their request or because they were undergoing other simultaneous procedures that required such anesthetic management.

All patients were given oral antiviral prophylaxis starting the day prior to treatment and extending until the completion of re-epithelialization. Oral antibiotics were given during the same time period as well. No oral or topical antifungal agents and no oral steroids were used.

Immediate postoperative care consisted of application of cold compresses, followed by lubrication of the treated skin surface with 1% hydrocortisone ointment in a base of plain white petrolatum. The patients were encouraged to gently wash the treated areas every 3 or 4 hours to prevent desiccation and crusting of the ointment and serum. Patients were seen in follow-up at day 2, day 7, and day 14 and month 1, month 3, and month 6 after the procedure was performed. Following complete re-epithelialization, makeup was applied if desired. Sunscreen and sun avoidance was advocated during the first several months postoperatively. An independent physician, not involved in the treatment, evaluated patient photographs. Patients were also given satisfaction questionnaires to fill out at the end of their 6 month follow-up period. Responses of the patients and the independent physician evaluator were graded and reported on a quartile scale: 0 = no improvement; 1 = <25% improvement; 2 = 26 – 50% improvement; 3 = 51 – 75% improvement; 4 = 75 – 100% improvement. All patients enrolled in the study completed the 6 month follow-up evaluation.

Normal expected side effects of erythema, edema, oozing, crusting; less common side effects of milia and dyschromia;

and complications of infection, and visible scarring were evaluated and graded by the patients and the investigators during and at the completion of the 6-month follow-up period. Overall post-operative results were evaluated and graded only at 6 months postoperatively.

RESULTS

All patients demonstrated significant clinical improvement in the problems for which the microablative CO₂ laser was employed (Figures 4-9). Improvement was noted in wrinkles, scars, striae, lentigines and the texture and color of the bronzed, sall-colored skin associated with solar elastosis. The best results in this single treatment protocol were in wrinkles, discrete pigment (lentigines), and solar elastosis. Less dramatic results were noted in acne scars and striae. As shown by Chapas et al,²⁴ the patients with acne scars who went on to have additional treatments did, in fact, demonstrate much more significant clinical improvement in the overall depth and appearance of their scarring. In addition, the ability to remove the scanning hand piece and replace it with a cutting/sculpting hand piece allows the user to sculpt and lower the contour of the edges of broad-based acne scars. Following this, the scanning hand

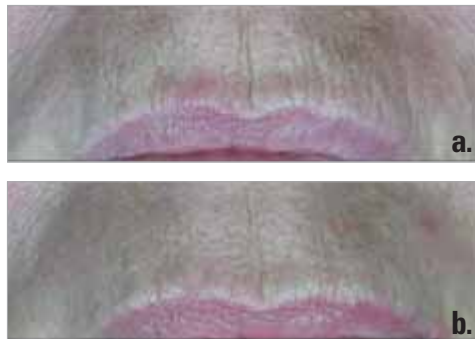

FIGURE 4. a) Upper lip prior to microablative laser treatment. **b)** Upper lip 6 months after a single treatment at 25 W, 1 ms, 500 μ m DOT spacing.

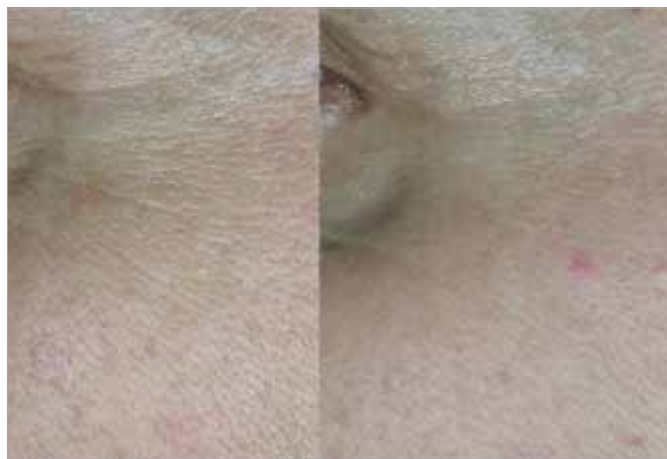

FIGURE 5. Before (left) and 6 months after (right) a single treatment with the microablative CO₂ laser at 22 W, 750 μ sec, 500 μ m DOT spacing.

piece is replaced and the entire cosmetic unit is treated in the micro-ablative resurfacing mode. This gave the best overall results in the treatment of acne scars, but was not part of this single treatment microablative resurfacing protocol.

All patients had some degree of erythema and edema following treatment; the number of days until the resolution of each depended upon the intensity of treatment. Similarly, those pa-

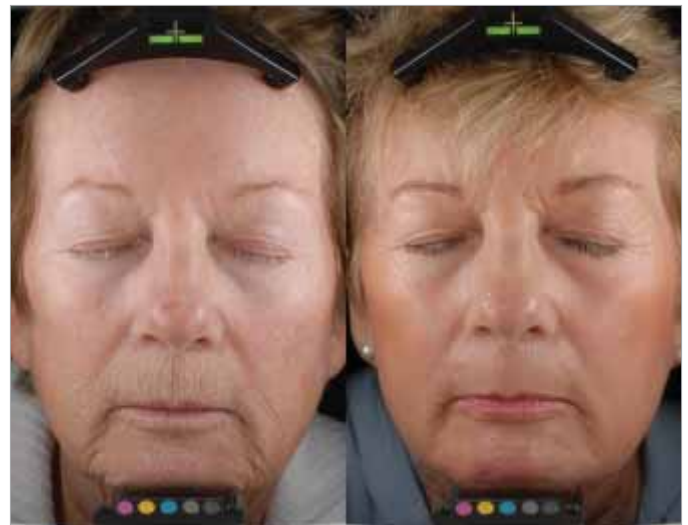

FIGURE 6. Before (left) and 6 months after (right) single treatment full face resurfacing with the microablative CO₂ laser. Perioral area treated at 30 W, 1700 μ sec, 200 μ m DOT spacing (2 passes). The periorbital area was treated at 20 W, 800 μ sec, 500 μ m DOT spacing (one pass) and the remainder of the face treated at 25 W, 1500 μ sec, 500 μ m (2 passes).

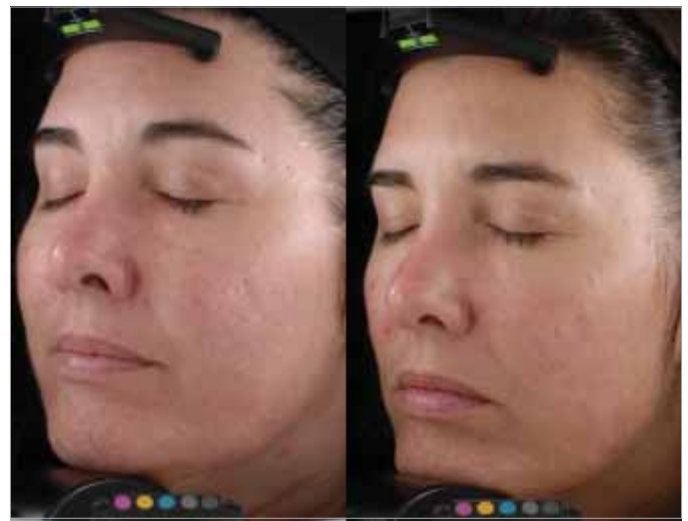

FIGURE 7. Before (left) and 6 months after (right) a single treatment with the microablative CO₂ laser at 30 W, 1500 μ sec, 500 μ m DOT spacing (2 passes).

tients treated at lower pulse energies had less oozing and crusting than those treated at higher pulse energies. Those treated at lower pulse energies noted a bronzing that was due to the slough of the microscopic cores of ablated epidermis and dermis; this bronzing usually resolved in 3 to 5 days. Similar to the recovery from standard, fully ablative CO₂ resurfacing, some patients treated at high pulse energies and tight DOT spacing experienced occasional milia during the postoperative period and some patients exhibited transient postinflammatory hyperpigmentation (PIH).

No patients had any residual PIH at 3 months following resurfacing. No cutaneous viral or bacterial infections occurred during the postoperative period and no adverse visible scarring has been noted. In addition, no hypopigmentation has yet been seen in the 6 to 9 month follow-up period of the patients included in this study. (Tables 1 to 3).

DISCUSSION

This preliminary study demonstrates the safety and efficacy of microablative CO₂ laser skin resurfacing with the SmartXide DOT CO₂ laser and the SmartPulse™ technology incorporated in this laser. The DOT therapy procedure was useful in the treatment of wrinkles, acne scars, striae, discrete epidermal pigment and the bronzed, sallow discoloration, and roughened texture of solar elastosis associated with sun-damaged skin. Histologic evidence of neocollagenesis is noted after 1 month and, based on studies in Europe, continues to evolve over a period of at least 1 year (personal communication, Giovanni Cannarozzo).

Standard, fully ablative CO₂ resurfacing penetrated, on the first pass, just through the dermal-epidermal junction into the superficial dermis. Multiple subsequent passes were required to penetrate deeper in the dermis. Using the Coherent Ultrapulse CO₂ laser with the computerized pattern generator, Burkhardt showed that the depth of injury did not increase after 3 passes and that injury depth seemed to be limited by the progressive desiccation of the superficial dermis.²⁵ The results of fully ablative CO₂ laser skin resurfacing were often dramatic, but the risk-benefit ratio was often too high. The dramatic clinical improvement seen in the appearance of wrinkles was due to the "new broad band of collagen," ie, a dermal scar, that formed

as the wound healed. This new and reordered collagen pattern was due to healing of the zones of ablation and healing of the zones of residual thermal damage surrounding the zones of ablation.²⁶⁻²⁸

It is the authors' belief that the histologic pulse profile of this microablative CO₂ laser, a broad zone of residual thermal damage surrounding a pyramidal zone of ablation, is what yields the considerable clinical improvement noted in treated patients (Figure 3). The zone of surrounding residual thermal damage is more important in the process of neocollagenesis than the depth of ablation. This is consistent with the results noted in earlier standard CO₂ laser resurfacing studies in the 1990s.²⁶⁻²⁸

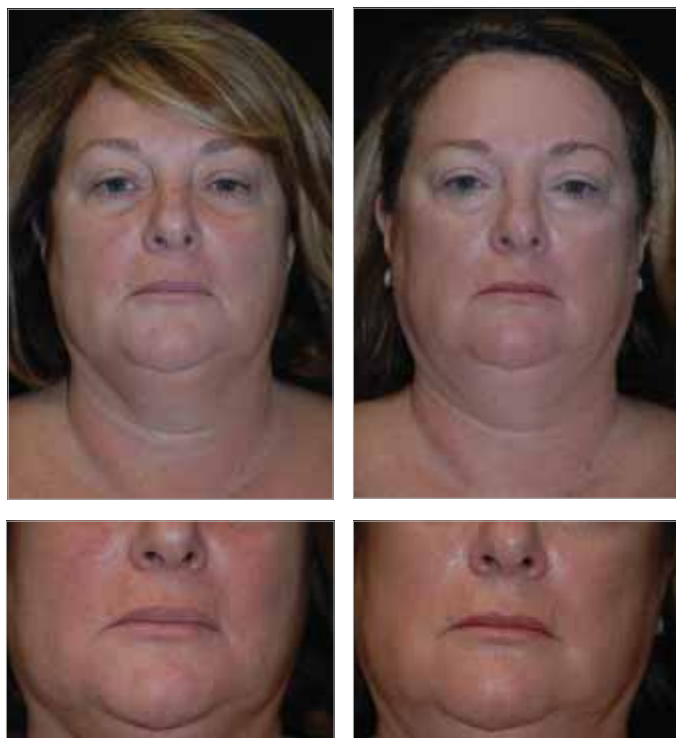

FIGURE 8. Before (left, top and bottom) and 6 months after (right, top and bottom) single treatment for full face microablative CO₂ laser resurfacing at 30 watts, 2000 μsec, 200 μm DOT spacing (1 pass).

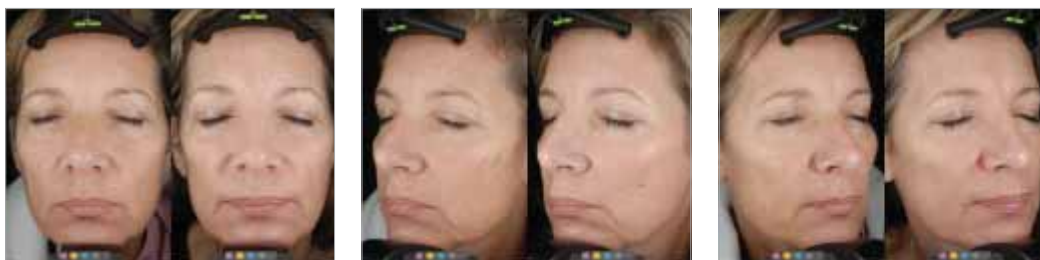

FIGURE 9. Before (left) and 6 months after (right) single treatment for full face and neck resurfacing with the microablative CO₂ laser at 30 W, 2000 μsec, 200 μm on the face and 25 W, 1000 μsec, 500 μm on the neck (1 pass).

CONCLUSION

Laser skin resurfacing with the microablative CO₂ laser has been shown in this study to be both safe and effective in the treatment wrinkles, scars, pigment and solar elastosis associated with sun damaged skin. The capacity of this laser to treat these epidermal and dermal problems with such a high safety profile, a low incidence of adverse side effects, and high patient satisfaction is a tribute to the significance and impact of this technology. This procedure employs a combination of fractional photothermolysis and the ablative effects of a CO₂ laser to produce a net result that yields profound clinical improvement. The authors' believe that this clinical improvement correlates to the changes seen in the tissue specimens submitted for histologic examination.

According to the historical evaluation of standard CO₂ laser skin resurfacing, hypopigmentation is often a late finding greater than 1 year and the postoperative observation period in this study ended at 6 months. Therefore, although no hypopigmentation has been noted in any of the study patients thus far, longer postoperative observation would be prudent in order to assess for late dyschromias. Further clinical experience with this versatile laser will also allow greater refinement of the parameters and algorithms to treat each clinical problem.

ACKNOWLEDGEMENTS

The authors would like to thank Geoffrey Gottlieb MD for the preparation and evaluation of histologic specimens.

TABLE 1.**Presence of side effects following ablative fractional resurfacing (N=32)**

Posttreatment	Edema	Erythema	Oozing or bronzing	Milia	Dyschromia (PIH)
2 days	32	32	32	0	0
7 days	32	32	24	0	0
14 days	21	27	2	1	0
1 month	15	3	0	6	13
3 months	0	0	0	2	0
6 months	0	0	0	0	0

TABLE 2.**Graded improvement by patients at various times postoperatively**

Posttreatment	Total patients (N=32)	Patients with rhytides (n = 18)	Patients with lentiginos and solar elastosis (n = 8)	Patients with acne scars (n = 4)	Patients with striae (n = 2)
1 month	3.75	3.89	3.75	3.50	3.00
3 months	3.56	3.83	3.63	2.75	2.50
6 months	3.53	3.78	3.75	2.50	2.50

TABLE 3.**Graded improvement by independent physician evaluator at various times postoperatively**

Posttreatment	Total patients (N=32)	Patients with rhytides (n = 18)	Patients with lentiginos and solar elastosis (n = 8)	Patients with acne scars (n = 4)	Patients with striae (n = 2)
1 month	3.69	3.89	3.88	3.00	2.50
3 months	3.56	3.89	3.75	2.50	2.00
6 months	3.47	3.83	3.75	2.00	2.00

DISCLOSURE

All authors were provided with lasers with which to perform this study by the manufacturer, DEKA.

REFERENCES

- Fitzpatrick RE, Goldman MP, Satur NM, Tope WD. Pulsed carbon dioxide laser resurfacing of photoaged facial skin. *Arch Dermatol.* 1996;132:395-402.
- Apfelberg, DB. The ultrapulse carbon dioxide laser with computer pattern generator automatic scanner for facial cosmetic surgery and resurfacing. *Ann Plast Surg.* 1996;36:522-529.
- Alster TS, Garg S. Treatment of facial rhytides with a high-energy pulsed carbon dioxide laser. *Plast Reconstr Surg.* 1996;98:791-794.
- Apfelberg, DB. Ultrapulse carbon dioxide laser with CPG scanner for full-face resurfacing for rhytides, photoaging, and acne scars. *Plast Reconstr Surg.* 1997;99:1817-1825.
- Alster TS, West TB. Resurfacing of atrophic facial acne scars with a high-energy, pulsed carbon dioxide laser. *Dermatol Surg.* 1996; 22:151-154.
- Apfelberg DB. A critical appraisal of high-energy pulsed carbon dioxide laser facial resurfacing for acne scars. *Ann Plast Surg.* 1997; 38:95-100.
- Bernstein LJ, Kauvar AN, Grossman MC, Geronemus RG. The short- and long-term side effects of carbon dioxide laser resurfacing. *Dermatol Surg.* 1997; 23:519-525.
- Nanni CA, Alster TS. Complications of carbon dioxide laser resurfacing: an evaluation of 500 patients. *Dermatol Surg.* 1998;24:315-320.
- Manuskiatti W, Fitzpatrick RE, Goldman MP. Long-term effectiveness and side effects of carbon dioxide laser resurfacing for photoaged facial skin. *J Am Acad Dermatol.* 1999;40:401-411.
- Ratner D, Tse Y, Marchell N, et al. Cutaneous laser resurfacing. *J Am Acad Dermatol.* 1999;41:365-389.
- Schwartz RJ, Burns AJ, Rohrich RJ, Barton FE, Byrd HS. Long term assessment of CO₂ facial laser resurfacing: aesthetic results and complications. *Plast Reconstr Surg.* 1999;103:593-601.
- Kauvar AN. Laser skin resurfacing: perspectives at the millennium. *Dermatol Surg.* 2000;26:174-177.
- Fitzpatrick RE. CO₂ laser resurfacing. *Dermatol Clin.* 2001;19:443-451.
- Fitzpatrick RE. Maximizing benefits and minimizing risk with CO₂ laser resurfacing. *Dermatol Clin.* 2002;20:77-86.
- Sadick NS. Update on non-ablative light therapy for rejuvenation: a review. *Lasers Surg Med.* 2003;32:120-128.
- Alexiades-Armenakas MR, Dover JS, Arndt KA. The spectrum of laser skin resurfacing: non-ablative, fractional, and ablative laser resurfacing. *J Am Acad Dermatol.* 2008;58:719-737.
- Manstein D, Herron GS, Sink RK, et al. Fractional photothermolysis: a new concept for cutaneous remodeling using microscopic patterns of thermal injury. *Lasers Surg Med.* 2004;34:426-438.
- Geronemus RG. Fractional photothermolysis: current and future applications. *Lasers Surg Med.* 2006;38:169-176.
- Clementoni MT, Gilardino P, Muti GF, et al. Non-sequential fractional ultrapulsed CO₂ resurfacing of photoaged facial skin: preliminary clinical report. *J Cosmet Laser Ther.* 2007;9:218-225.
- Hantash BM, Bedi VP, Kapadia B, et al. In vivo histological evaluation of a novel ablative fractional resurfacing device. *Lasers Surg Med.* 2007;39:96-107.
- Hantash BM, Bedi VP, Chan KF, Zachary CB. Ex vivo histological characterization of a novel ablative fractional resurfacing device. *Lasers Surg Med.* 2007;39:87-95.
- Rahman Z, Tanner H, Tournas J, et al. Ablative fractional resurfacing for the treatment of photodamage and laxity. *Lasers Surg Med.* 2007;39(s19):15.
- Weiss RA, Weiss MA, Beasley KL. Prospective clinical trial of a fixed spacing array computer scanned fractional CO₂ laser for rhytides. *Lasers Surg Med.* 2007;39(s19):16.
- Chapas AM, Brightman L, Sukal S, et al. Successful treatment of acneiform scarring with CO₂ fractional resurfacing. *Lasers Surg Med.* 2008;40:381-386.
- Burkhardt B, Maw R. Are more passes better? Safety versus efficacy with the pulsed CO₂ laser. *Plast Reconstr Surg.* 1997;100:1531-1534.
- Alster TS, Nanni CA, Williams CA. Comparison of four carbon dioxide resurfacing lasers: a clinical and histopathologic evaluation. *Dermatol Surg.* 1999;25:153-159.
- Grover S, Apfelberg DB, Smoller B. Effects of varying density patterns on depth of penetration in facial skin utilizing the carbon dioxide laser with automated scanner. *Plast Reconstr Surg.* 1999;104:2247-2252.
- Ross EV, Naseef GS, McKinlay JR, et al. Comparison of carbon dioxide laser, erbium:YAG laser, dermabrasion, and dermatome: a study of thermal damage, wound contraction, and wound healing in a live pig model: implications for skin resurfacing. *J Am Acad Dermatol.* 2000;42:92-105.

ADDRESS FOR CORRESPONDENCE**Robert H. Gotkin MD FACS**

625 Park Avenue

New York, NY 10065

Phone 212-794-4000

e-mail.....rhgotkin@cosmetiqueMD.com